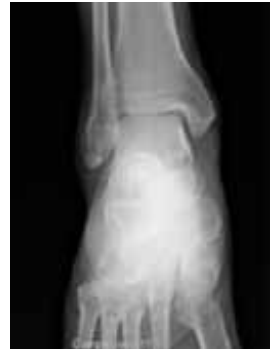

X-ray (Radiography), Bone

What is Bone X-ray (Radiography)?

An x-ray (radiograph) is a noninvasive medical test that helps physicians diagnose and treat medical conditions. Imaging with x-rays involves exposing a part of the body to a small dose of ionizing radiation to produce pictures of the inside of the body. X-rays are the oldest and most frequently used form of medical imaging.

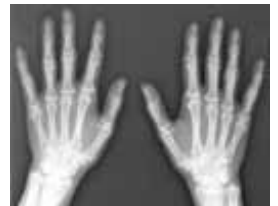A bone x-ray makes images of any bone in the body, including the hand, wrist, arm, elbow, shoulder, foot, ankle, leg (shin), knee, thigh, hip, pelvis or spine.



What are some common uses of the procedure?

A bone x-ray is used to:

- diagnose broken bones or joint dislocation.
- demonstrate proper alignment and stabilization of bony fragments following treatment of a fracture.
- guide orthopedic surgery, such as spine repair/fusion, joint replacement and fracture reductions.
- look for injury, infection, arthritis, abnormal bone growths, bony changes seen in metabolic conditions.
- assist in the detection and diagnosis of bone cancer.
- locate foreign objects in soft tissues around or in bones.



How should I prepare?

Most bone x-rays require no special preparation.


You may be asked to remove some or all of your clothes and to wear a gown during the exam. You may also be asked to remove jewelry, dentures, eye glasses and any metal objects or clothing that might interfere with the x-ray images.

Women should always inform their physician and x-ray technologist if there is any possibility that they are pregnant. Many imaging tests are not performed during pregnancy so as not to expose the fetus to radiation. If an x-ray is necessary, precautions will be taken to minimize radiation exposure to the baby. See the Safety page (www.RadiologyInfo.org/en/safety/) for more information about pregnancy and

x-rays.

What does the equipment look like?

The equipment typically used for bone x-rays consists of an x-ray tube suspended over a table on which the patient lies. A drawer under the table holds the x-ray film or image recording plate. Sometimes the x-ray is taken with the patient standing upright, as in cases of knee x-rays.



A portable x-ray machine is a compact apparatus that can be taken to the patient in a hospital bed or the emergency room. The x-ray tube is connected to a flexible arm that is extended over the patient while an x-ray film holder or image recording plate is placed beneath the patient.

How does the procedure work?

X-rays are a form of radiation like light or radio waves. X-rays pass through most objects, including the body. Once it is carefully aimed at the part of the body being examined, an x-ray machine produces a small burst of radiation that passes through the body, recording an image on photographic film or a special digital image recording plate.

Different parts of the body absorb the x-rays in varying degrees. Dense bone absorbs much of the radiation while soft tissue, such as muscle, fat and organs, allow more of the x-rays to pass through them. As a result, bones appear white on the x-ray, soft tissue shows up in shades of gray and air appears black.

Until recently, x-ray images were maintained as hard film copy (much like a photographic negative). Today, most images are digital files that are stored electronically. These stored images are easily accessible and are frequently compared to current x-ray images for diagnosis and disease management.

How is the procedure performed?

The technologist, an individual specially trained to perform radiology examinations, positions the patient on the x-ray table and places the x-ray film holder or digital recording plate under the table in the area of the body being imaged. When necessary, sandbags, pillows or other positioning devices will be used to help you maintain the proper position. A lead apron may be placed over your pelvic area or breasts when feasible to protect from radiation.

You must hold very still and may be asked to keep from breathing for a few seconds while the x-ray picture is taken to reduce the possibility of a blurred image. The technologist will walk behind a wall or into the next room to activate the x-ray machine.

You may be repositioned for another view and the process is repeated. Two or three images (from different angles) will typically be taken around a joint (knee, elbow or wrist).

An x-ray may also be taken of the unaffected limb, or of a child's growth plate (where new bone is

forming), for comparison purposes.

When the examination is complete, you will be asked to wait until the radiologist determines that all the necessary images have been obtained.

A bone x-ray examination is usually completed within five to 10 minutes.

What will I experience during and after the procedure?

A bone x-ray examination itself is a painless procedure.

You may experience discomfort from the cool temperature in the examination room. You may also find holding still in a particular position and lying on the hard examination table uncomfortable, especially if you are injured. The technologist will assist you in finding the most comfortable position possible that still ensures x-ray image quality.

Who interprets the results and how do I get them?

A radiologist, a physician specifically trained to supervise and interpret radiology examinations, will analyze the images and send a signed report to your primary care or referring physician, who will discuss the results with you.

What are the benefits vs. risks?

Benefits

- Bone x-rays are the fastest and easiest way for a physician to view and assess broken bone and joint abnormalities, such as arthritis and spine injuries.
- X-ray equipment is relatively inexpensive and widely available in emergency rooms, physician offices, ambulatory care centers, nursing homes and other locations, making it convenient for both patients and physicians.
- Because x-ray imaging is fast and easy, it is particularly useful in emergency diagnosis and treatment.
- No radiation remains in a patient's body after an x-ray examination.
- X-rays usually have no side effects in the diagnostic range.

Risks

- There is always a slight chance of cancer from excessive exposure to radiation. However, the benefit of an accurate diagnosis far outweighs the risk.
- The effective radiation dose from this procedure depends on the part of the body being examined. For spine x-rays, the dose is about 1.5 mSv, which is about the same as the average person receives from background radiation in 6 months. For x-rays of extremities, the dose is about 0.001 mSv, which is about the same as the average person receives from background radiation in less than 1 day. See the Safety page (www.RadiologyInfo.org/en/safety) for more information

about radiation dose.

- Women should always inform their physician or x-ray technologist if there is any possibility that they are pregnant. See the Safety page (www.RadiologyInfo.org/en/safety/) for more information about pregnancy and x-rays.

A Word About Minimizing Radiation Exposure

Special care is taken during x-ray examinations to use the lowest radiation dose possible while producing the best images for evaluation. National and international radiology protection councils continually review and update the technique standards used by radiology professionals.

State-of-the-art x-ray systems have tightly controlled x-ray beams with significant filtration and dose control methods to minimize stray or scatter radiation. This ensures that those parts of a patient's body not being imaged receive minimal radiation exposure.

What are the limitations of Bone X-ray (Radiography)?

While x-ray images are among the clearest, most detailed views of bone, they provide little information about muscles, tendons or joints.

An MRI may be more useful in identifying ligament tears and joint effusions in knee or shoulder injuries and in imaging the spine, because both the bones and the spinal cord can be evaluated. MRI can also detect a bone bruise when no crack is visible on x-ray images.

CT is being used widely to assess trauma patients in emergency departments. A CT scan can image complicated fractures, subtle fractures or dislocations. In elderly or patients with osteoporosis, a hip fracture may be clearly seen on a CT scan, while it may be barely seen, if at all, on a hip x-ray.

For suspected spine injury, 3-D reconstructed CT images can be made without additional radiation exposure to help the diagnosis and treatment of the individual patient's condition.

Ultrasound imaging, which uses sound waves instead of ionizing radiation to create diagnostic images, has also been useful for injuries around joints, and in evaluating the hips of children with congenital problems.

Disclaimer

This information is copied from the RadiologyInfo Web site (<http://www.radiologyinfo.org>) which is dedicated to providing the highest quality information. To ensure that, each section is reviewed by a physician with expertise in the area presented. All information contained in the Web site is further reviewed by an ACR (American College of Radiology) - RSNA (Radiological Society of North America) committee, comprising physicians with expertise in several radiologic areas.

However, it is not possible to assure that this Web site contains complete, up-to-date information on any particular subject. Therefore, ACR and RSNA make no representations or warranties about the suitability of this information for use for any particular purpose. All information is provided "as is" without express or implied warranty.

Please visit the RadiologyInfo Web site at <http://www.radiologyinfo.org> to view or download the latest information.

Note: Images may be shown for illustrative purposes. Do not attempt to draw conclusions or make diagnoses by comparing these images to other medical images, particularly your own. Only qualified physicians should interpret images; the radiologist is the physician expert trained in medical imaging.

Copyright

This material is copyrighted by either the Radiological Society of North America (RSNA), 820 Jorie Boulevard, Oak Brook, IL 60523-2251 or the American College of Radiology (ACR), 1891 Preston White Drive, Reston, VA 20191-4397. Commercial reproduction or multiple distribution by any traditional or electronically based reproduction/publication method is prohibited.

Copyright © 2010 Radiological Society of North America, Inc.